

The Posterolateral Attachments of the Knee

A Qualitative and Quantitative Morphologic Analysis of the Fibular Collateral Ligament, Popliteus Tendon, Popliteofibular Ligament, and Lateral Gastrocnemius Tendon*

Robert F. LaPrade,†‡ MD, PhD, Thuan V. Ly,† MD, Fred A. Wentorf,† MS, and Lars Engebretsen,§ MD, PhD

From the †Department of Orthopaedic Surgery, University of Minnesota, Minneapolis, Minnesota, and the §Department of Orthopaedic Surgery, University of Oslo, Oslo, Norway

Background: Quantitative descriptions of the attachment sites of the main posterolateral knee structures have not been performed.

Purpose: To qualitatively and quantitatively determine the anatomic attachment sites of these structures and their relationships to pertinent bony landmarks.

Study Type: Cadaveric study.

Methods: Dissections were performed and measurements taken on 10 nonpaired fresh-frozen cadaveric knees.

Results: The fibular collateral ligament had an average femoral attachment slightly proximal (1.4 mm) and posterior (3.1 mm) to the lateral epicondyle. Distally, it attached 8.2 mm posterior to the anterior aspect of the fibular head. The popliteus tendon had a constant broad-based femoral attachment at the most proximal and anterior fifth of the popliteal sulcus. The popliteus tendon attachment on the femur was always anterior to the fibular collateral ligament. The average distance between the femoral attachments of the popliteus tendon and fibular collateral ligament was 18.5 mm. The popliteofibular ligament had two divisions—anterior and posterior—in all cases. The average attachment of the posterior division was 1.6 mm distal to the posteromedial aspect of the tip of the fibular styloid process and the anterior division attached 2.8 mm distal to the anteromedial aspect of the tip of the fibular styloid process.

Conclusions: These structures had a consistent attachment pattern. This information will prove useful in the study of anatomic repair and reconstruction of the posterolateral structures of the knee.

© 2003 American Orthopaedic Society for Sports Medicine

Over the past decade, there has been an increasing number of publications better defining not only the anatomy of the posterolateral corner of the knee, but also the diagnosis and treatment of injuries to this area.^{11–13, 16, 22–24, 26–28, 31}

Despite these advances, posterolateral rotatory instability of the knee is still difficult to diagnose and treat clinically. Although the posterolateral corner of the knee contains many structures, several studies have reported that the fibular collateral ligament, the popliteus tendon, and the popliteofibular ligament are the main contributors to static stabilization of the posterolateral corner of the knee.^{6, 7, 20, 22, 23, 27, 28, 31} The functional contributions of these structures, as determined by the selective ligament cutting technique, are restraining varus, external rotation, and coupled posterior translation and external rotation of the tibia on the femur.^{6, 7, 27}

* Presented at the interim meeting of the AOSSM, Orlando, Florida, March 2000.

‡ Address correspondence and reprint requests to Robert F. LaPrade, MD, PhD, Department of Orthopaedic Surgery, University of Minnesota, 2450 Riverside Avenue, R200, Minneapolis, MN 55454.

No author or related institution has received any financial benefit from research in this study. See "Acknowledgments" for funding information.

To our knowledge, there have been no studies on the qualitative and quantitative anatomic relationships of the posterolateral knee structures. To achieve an anatomic repair of an avulsed structure, one must know the attachment site (or sites) of the avulsed ligament or tendon. At the time of surgery, it can be difficult to identify the attachment sites of the fibular collateral ligament, popliteus tendon, and popliteofibular ligament. This is especially true in cases of chronic injury of the posterolateral structures. Retraction and scarring can make it difficult to identify the structures' normal attachment sites. Although we have found that the lateral gastrocnemius tendon is rarely avulsed in posterolateral knee injuries,^{12,13} it has been included in surgical reconstructions such as advancement procedures.⁹ Also, because the lateral gastrocnemius tendon is rarely injured,¹³ it can serve as a reference structure for identifying other posterolateral knee structure attachment sites.

We believe that identification of these attachment sites is as important for repair or reconstruction of the posterolateral knee structures as identification of the attachment sites of the cruciate ligaments proved to be for ACL and PCL repairs and reconstructions.^{1,2,4,9,13} With this in mind, we determined to identify and measure, using references to relevant bony landmarks, the anatomic locations of the attachment sites of the fibular collateral ligament, popliteus tendon, popliteofibular ligament, and lateral gastrocnemius tendon.

MATERIALS AND METHODS

Gross Anatomy Dissections

Dissections were performed on 10 nonpaired fresh-frozen cadaveric knees with no signs of previous surgery, knee abnormalities, or disease. The specimens' ages ranged from 57 to 80 years (mean, 63). All of the knees had at least 20 cm of bone and soft tissue proximal and distal to the joint line. Each knee was frozen at -20° and allowed to thaw overnight before dissection. Dissection began with removal of the skin and subcutaneous tissues to expose the muscles and overlying fascia. Next, all muscles and soft tissues proximal to the adductor tubercle and the supracondylar process (where the lateral intermuscular septum terminates) of the femur were removed to bone. In addition, distal to the level of the tibial tubercle, all muscles and soft tissues were dissected off the tibia and the fibula. This allowed for mounting of the femur and tibia/fibula into pots filled with polymethyl methacrylate and for placement into a knee testing machine for analysis.¹⁵ Before specimens were potted in polymethyl methacrylate, metal screws were placed into the ends of the femur and tibia/fibula to allow for secure fixation and to prevent rotation during analysis. The specimens were kept moist with saline-soaked gauze during the potting procedure.

Once potting was completed, the popliteal fossa and the lateral aspect of the knee were carefully dissected to identify the lateral gastrocnemius tendon, popliteus muscle and tendon, popliteofibular ligament, fibular collateral ligament, insertion of the iliotibial band onto Gerdy's tu-

bercle, and the termination of the lateral intermuscular septum (Fig. 1). After initial measurements were performed, the attachment sites of these structures were identified.

Anatomic Measurements

To quantitatively measure the insertion sites of the measured structures and bony landmarks, we used a computer-controlled video motion analysis capture system (Qualysis, Inc., Glastonbury, Connecticut). This digitizing system allowed us to record the periphery of each measured structure by placing the knee in a previously calibrated videogrammetric block. A fine-point marker with predetermined x, y, and z infrared-emitting sphere coordinates at its top was used to measure the location of the structure or structures of interest. The accuracy and resolution of this measurement technique was then calculated by repeated measurement of points within a three-dimensional grid with a known accuracy of 0.001 mm. The output of the video motion analysis measurement system and the known position on the grid were compared. The accuracy of this measurement system under these testing conditions was 0.1 mm.

Using the fine-point marker, we first measured the proximal attachment of the fibular collateral ligament on the lateral femoral condyle and its distal attachment on the lateral fibular head. At each respective attachment site, we traced an outline of the attachment site while the motion analysis video system captured its quantitative location immediately after the attachment site was dissected off the bone. A similar approach was also used for measurement of the popliteus tendon attachment in the popliteal sulcus and the lateral gastrocnemius tendon attachment at the supracondylar process of the femur. The total cross-sectional area of the attachment sites for these structures was then calculated. In addition to these measurements, a goniometer was used to measure the angle between the long axis of the femoral shaft and the popliteus tendon to determine when this structure completely entered the popliteal sulcus.

The two divisions of the popliteofibular ligament were then measured individually. First, before removal of the popliteus tendon from its femoral attachment, the angle between the popliteus tendon and the popliteofibular ligament and the angle the popliteofibular ligament made to the horizontal plane were measured. The lateral attachments of the anterior and posterior divisions of the popliteofibular ligament on the fibula were located by marking the proximal and distal borders, followed by outlining each distal attachment site. The medial attachments of the anterior and posterior divisions of the popliteofibular ligament to the popliteus complex were quantified by measuring the proximal and distal attachment sites of each division at the musculotendinous junction. Because the attachment sites of both divisions were a thin line rather than a broad attachment (as with the fibular collateral ligament, lateral gastrocnemius tendon, and popliteus tendon), the cross-sectional area for the attachments of these structures was not calculated.

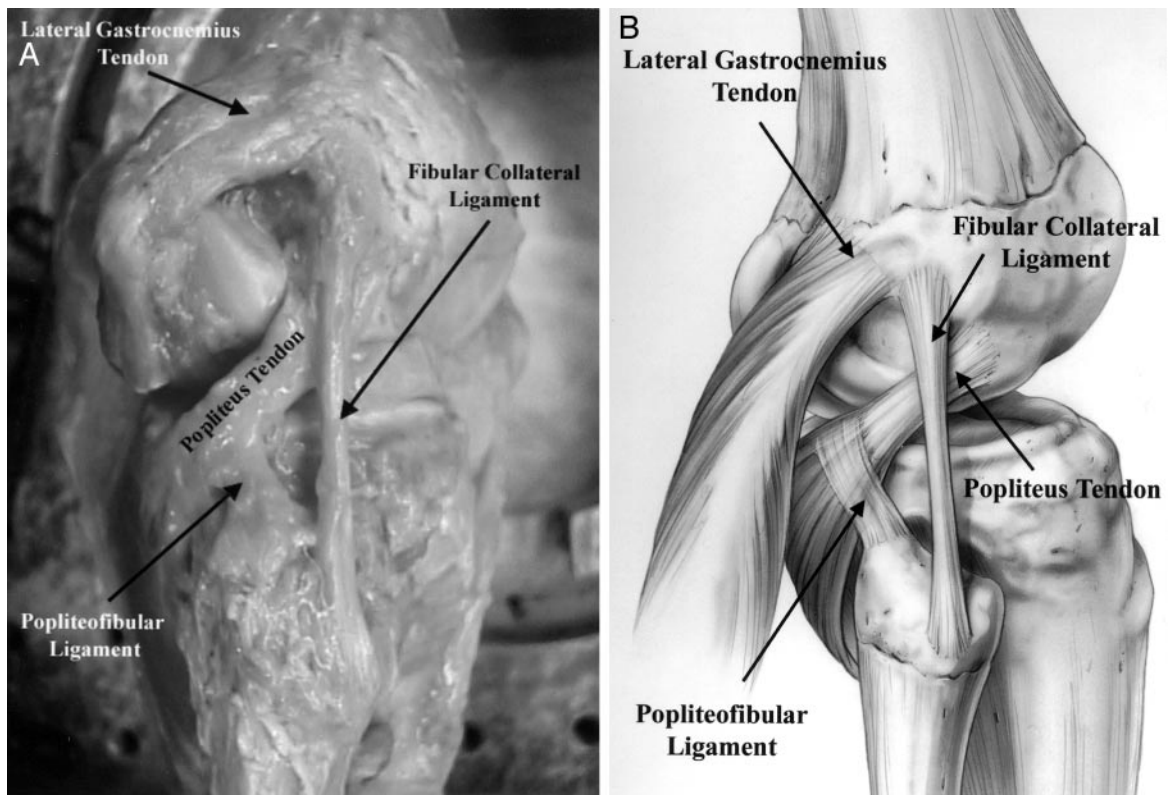


Figure 1. Photograph (A) and illustration (B) demonstrating the isolated fibular collateral ligament, popliteus tendon, popliteofibular ligament, and lateral gastrocnemius tendon (lateral view, right knee).

After quantitative measurement of the attachment sites of each posterolateral knee structure was completed, the distances from the attachment sites of each structure to specific bony landmarks were measured. These reference points were the supracondylar process, the lateral epicondyle, the lateral aspect of the tibial tubercle, Gerdy's tubercle, the fibular head (proximal, anterior, and posterior border), and the fibular styloid process (proximal, medial, and lateral border).

RESULTS

All reference measurements refer to the midportion of the attachment sites of each structure. Measurements to the lateral epicondyle, supracondylar process, and Gerdy's tubercle were to their centers, whereas measurements to the tibial tubercle were to its lateral edge.

Fibular Collateral Ligament

We found that the average fibular collateral ligament attachment on the femur was slightly proximal (1.4 mm; range, 0.8 to 2.7) and posterior (3.1 mm; range, 2.3 to 4.4) to the lateral epicondyle (Figs. 1 and 2). The main femoral attachment resided in a small bony depression just posterior to the lateral epicondyle. In addition, some fibers extended proximally and anteriorly over the lateral epicondyle in a fan-like fashion. The average cross-sectional

area of the fibular collateral ligament attachment site on the femur was 0.48 cm^2 (range, 0.43 to 0.52). The average distance between the attachments of the fibular collateral ligament and the popliteus tendon on the femur was 18.5 mm (range, 16.8 to 22.9) (Fig. 2).

As the fibular collateral ligament coursed distally and attached on the lateral aspect of the fibular head, its average attachment was 8.2 mm (range, 6.8 to 9.7) posterior to the anterior margin of the fibular head and 28.4 mm (range, 25.1 to 30.6) distal to the tip of the fibular styloid process (Table 1). The average cross-sectional area of the attachment on the fibular head was 0.43 cm^2 (range, 0.39 to 0.50). The fibular collateral ligament attachment was, on average, 38% (range, 28% to 46%) of the total width of the fibular head (anterior to posterior) from the anterior edge of the fibular head. The majority of the distal attachment was found in a bony depression that extended to approximately the distal one-third of the lateral aspect of the fibular head (Figs. 1 and 2). The remaining fibers extended further distally along with the peroneus longus fascia.^{25,26} The average total length of the fibular collateral ligament between its attachment sites was 69.6 mm (range, 62.6 to 73.5).

Popliteus Tendon

As the popliteus muscle coursed proximally and laterally over the posterolateral knee from its attachment on the

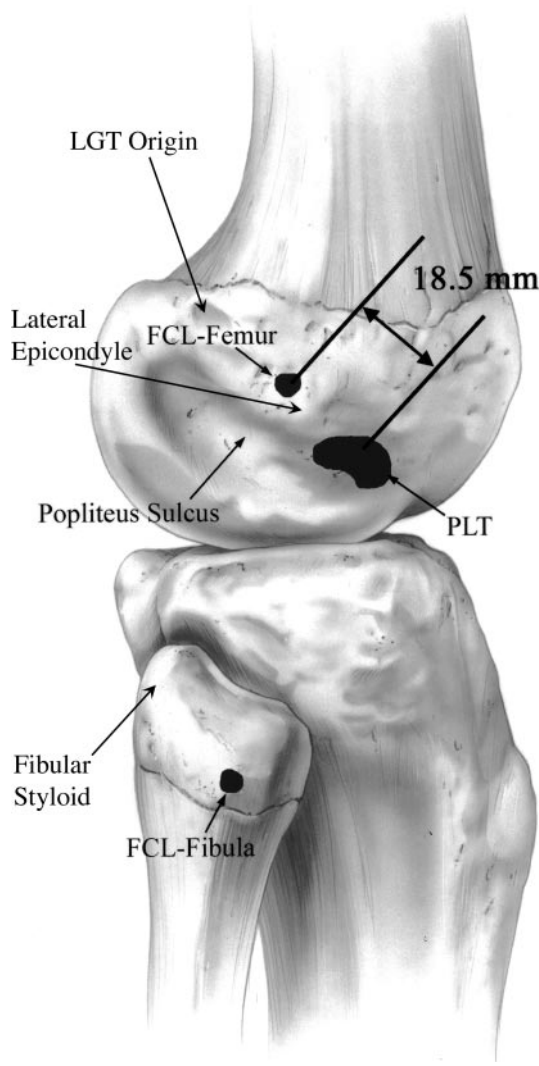


Figure 2. The attachment sites of the fibular collateral ligament (FCL) on the femur and fibula and the popliteus tendon (PLT) in the popliteus sulcus of the femur (lateral view, right knee). In addition, the average distance between the femoral attachment sites is noted. LGT, lateral gastrocnemius tendon.

posteromedial tibia, it gave rise to the popliteus tendon at the lateral one-third of the popliteal fossa. The popliteo-fibular ligament attached to the popliteus complex at the musculotendinous junction. The popliteus tendon then became intraarticular as it coursed anterolaterally around the posterior aspect of the lateral femoral condyle and ran medial to the fibular collateral ligament before attaching on the popliteal sulcus (Fig. 1). The average total cross-sectional area of the popliteal sulcus was 3.4 cm² (range, 2.9 to 3.8). The average cross-sectional area of the attachment site of the popliteus tendon was 0.59 cm² (range, 0.53 to 0.62). The popliteus tendon attachment was at the most anterior fifth of the popliteal sulcus, and its attachment was on the proximal half of the sulcus at this position. The popliteus tendon attachment on the femur was

TABLE 1
Quantitative Relationships of the Fibular Collateral Ligament to Other Posterolateral Knee Structures and Bony Landmarks^a

Relationship	Mean distance (mm)	Range (mm)
Proximal FCL to PLT	18.5	16.8–22.9
Proximal FCL proximal to lateral epicondyle	1.4	0.8– 2.7
Proximal FCL posterior to lateral epicondyle	3.1	2.3– 4.4
Proximal FCL to supracondylar process	54.3	50.4–61.3
Length of FCL	69.6	62.6–73.5
Distal FCL to anterior edge of fibular head	8.2	6.8– 9.7
Width of fibular head (anterior to posterior) at FCL attachment site	36.3	31.2–40.7
Distal FCL to fibular styloid tip	28.4	25.1–30.6
Distal FCL to Gerdy's tubercle	43.6	39.3–48.2
Distal FCL to tibial tubercle	75.1	70.4–81.2

^a FCL, fibular collateral ligament; PLT, popliteus tendon; LGT, lateral gastrocnemius tendon.

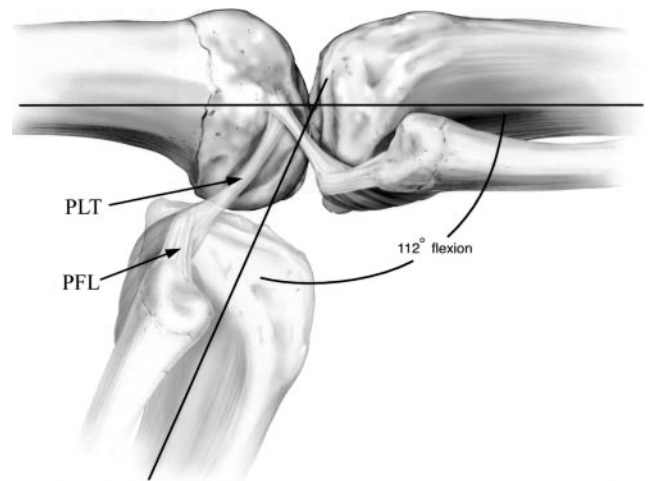


Figure 3. The position of the popliteus tendon (PLT) to the popliteus sulcus with the knee in full extension and at an average of 112° of knee flexion (ghosted view) (lateral view, right knee). PFL, popliteofibular ligament.

always anterior to the fibular collateral ligament femoral attachment.

With the knee near extension, the popliteus tendon was anteriorly subluxated from the popliteal sulcus over the lateral aspect of the lateral femoral condyle. It did not completely enter the confines of the popliteal sulcus until the knee was flexed to an average of 112° (range, 105° to 130°) (Fig. 3). The average total length of the popliteus

tendon from its femoral attachment to its musculotendinous junction was 54.5 mm (range, 50.5 to 61.2).

Popliteofibular Ligament

The popliteofibular ligament originated at the musculotendinous junction of the popliteus and formed an average 83° (range, 78° to 88°) angle with its medial attachment site. Its average angle to the horizontal plane was 37° (range, 22° to 40°). The popliteofibular ligament consistently had two divisions (anterior and posterior) (Fig. 4). The average distances from the attachments and the relationships of the anterior and posterior divisions of the popliteofibular ligament to other specific bony landmarks are listed in Table 2.

Proximomedially, the anterior division of the popliteofibular ligament attached to the popliteus complex at the proximolateral musculotendinous junction. The distolateral attachment of the anterior division was located on the anterior downslope of the medial aspect of the fibular styloid process. In addition, it had fibers extending to the lateral tibia in close proximity to the proximal anterior tibiofibular ligament. The average fibular attachment of

the anterior division of the popliteofibular ligament was 2.8 mm (range, 1.2 to 3.8) distal to the tip of the fibular styloid process on its anteromedial downslope. The average width of the anterior division's attachment on the anteromedial fibular styloid process was 2.6 mm (range, 1.8 to 3.4).

The proximomedial attachment of the posterior division was also located at the lateral aspect of the popliteus musculotendinous junction. The distolateral attachment of the posterior division was at the tip and posteromedial aspect of the fibular styloid process. The average attachment of the posterior division was 1.6 mm (range, 0.6 to 2.8) distal to the tip of the fibular styloid process on its posteromedial downslope. The average width of the posterior division at its fibular styloid attachment was 5.8 mm (range, 3.6 to 7.7). In all knees, the posterior division of the popliteofibular ligament was larger than the anterior division.

Lateral Gastrocnemius Tendon

The lateral gastrocnemius tendon was at the far lateral aspect of the lateral gastrocnemius muscle belly. At the level of the fabella or cartilaginous fabella-analog,^{10,26} it became adherent and inseparable from the meniscofemoral portion of the lateral capsule proximal to the fabella. The lateral gastrocnemius tendon consistently originated near or at the supracondylar process of the distal femur (Fig. 1). In 8 of the 10 knees, the attachment was on the supracondylar process. In the other two knees, the lateral gastrocnemius tendon attached slightly distal and posterior to the supracondylar process. In all 10 knees, a fabellofibular ligament, defined as the distal edge of the cap-

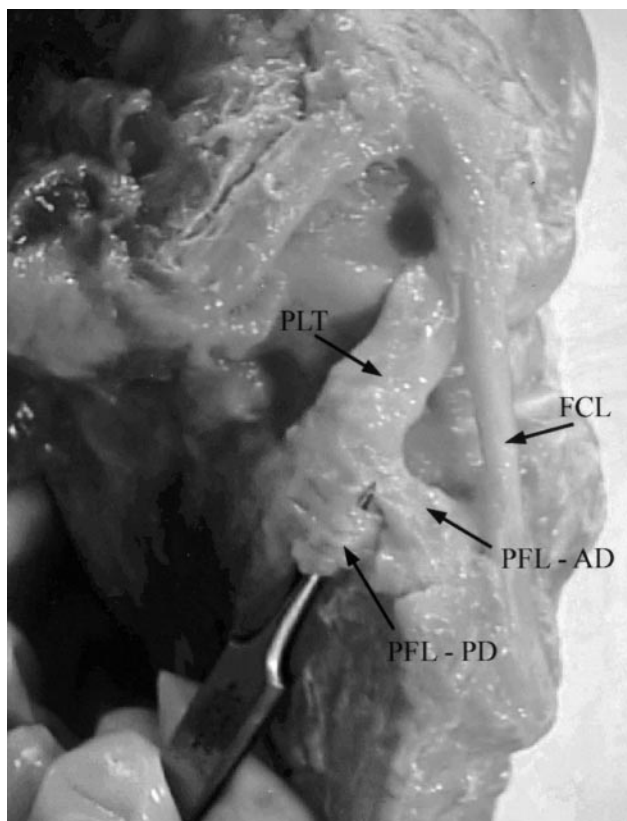


Figure 4. Attachment sites of the anterior (AD) and posterior (PD) (over surgical pickups) divisions of the popliteofibular ligament (PFL) at the popliteus musculotendinous junction (medially) and the medial aspect of the fibular head and fibular styloid process (laterally) (posterior view, right knee). FCL, fibular collateral ligament; PLT, popliteus tendon.

TABLE 2
Quantitative Relationships of the Bony Attachments of the Popliteus Tendon and Popliteofibular Ligament to Other Posterolateral Knee Structures and Bony Landmarks^a

Relationship	Mean distance (mm)	Range (mm)
PLT origin to popliteus musculotendinous junction	54.5	50.5–61.2
PLT origin to lateral epicondyle	15.8	11.2–18.6
PFL posterior division attachment to tip of fibular styloid	1.6	0.6– 2.8
Width of posterior division PFL along fibular styloid	5.8	3.6– 7.7
PFL anterior division attachment to tip of fibular styloid	2.8	1.2– 3.8
Width of anterior division PFL at popliteus musculotendinous junction	2.6	1.8– 3.4
Width of anterior division of PFL along fibular styloid	3.1	2.3– 3.7
Width of posterior division of PFL at popliteus musculotendinous junction	6.5	5.3– 8.2

^a PLT, popliteus tendon; PFL, popliteofibular ligament; FCL, fibular collateral ligament.

TABLE 3
Quantitative Relationships of the Lateral Gastrocnemius
Tendon Femoral Attachment to Other Posterolateral Knee
Structures^a

Relationship	Mean distance (mm)	Range (mm)
LGT to FCL attachment on femur	13.8	11.3–16.4
LGT to PLT attachment on femur	28.4	23.1–36.3
LGT to lateral epicondyle	17.2	15.8–20.3

^a LGT, lateral gastrocnemius tendon; FCL, fibular collateral ligament; PLT, popliteus tendon.

sular arm of the short head of the biceps femoris,^{12,26} was identified.

The average attachment of the lateral gastrocnemius tendon was 13.8 mm (range, 11.3 to 16.4) posterior to the fibular collateral ligament attachment on the femur (Table 3). The average distance from the lateral gastrocnemius tendon attachment on the femur to the popliteus tendon attachment was 28.4 mm (range, 23.1 to 36.3).

DISCUSSION

Part of the catalyst for this study was our clinical attempts at both repair and reconstruction of posterolateral knee structures in both acute and chronic conditions of injury. As noted earlier, there can be some difficulty in determining the normal attachment sites of the posterolateral knee structures covered in this study. Correspondingly, there has been a lack of precise anatomic descriptions that would allow for repairs and reconstructions to be performed with reference to specific bony landmarks. With the recent interest in posterolateral knee anatomy, biomechanics, and injuries, many studies have qualitatively defined the structures that compose the posterolateral knee and described their functional contributions.^{6,7,11–13,16,22,23,26,29,30,32} However, to our knowledge, quantification of the attachment sites of the fibular collateral ligament, popliteus tendon, popliteofibular ligament, and lateral gastrocnemius tendon and their relationship to the bony anatomy has not been performed previously.

It took many years before it became evident that quantitative anatomic and biomechanical studies of the native ACL were crucial as a basis for choosing appropriate graft location and developing proper ACL reconstruction techniques. It is believed that grafts that accurately reproduce the normal anatomy of the ACL produce the best results.^{1,2,4,5} Harner et al.⁸ acknowledged this concept about the importance of understanding the qualitative and quantitative anatomy of the ACL and used a similar approach in their PCL anatomy study. Their study quantitated the attachment sites of the anterolateral and posteromedial bundles of the PCL. They speculated that accurate anatomic placement of the anterolateral bundle would help restore its function. Other authors have expanded on their study in attempts to reconstruct both bundles of the PCL.^{3,17} Understanding the anatomy, ori-

entation, and attachment sites of the cruciate ligaments was important for the development of successful techniques of ACL and PCL reconstructions. Likewise, the results of our study will prove useful to the study of anatomic repairs and the development of anatomic reconstructions for posterolateral knee instability.

A main goal of this study was to achieve a better understanding of the spatial relationships and attachment sites of the fibular collateral ligament, popliteus tendon, and lateral gastrocnemius tendon on the lateral femoral condyle. We found that, relative to the lateral epicondyle, the lateral gastrocnemius tendon was posterosuperior, the popliteus tendon was anteroinferior, and the fibular collateral ligament was proximoposterior (Figs. 1 and 2). Contrary to anatomy textbooks, which report that the fibular collateral ligament attaches to the lateral epicondyle,²¹ we found that the average fibular collateral ligament attachment was proximal (1.4 mm) and posterior (3.1 mm) to the lateral epicondyle. We found that the majority of the fibular collateral ligament attachment resided in a bony depression, or saddle, adjacent to the lateral epicondyle. Although in some knees a few fibers extended to the lateral epicondyle, we found that the fibular collateral ligament did not have a significant attachment to the lateral epicondyle itself.

Regarding the popliteus tendon attachment on the femoral condyle, we agree with Stäubli et al.^{22,23} that it inserts proximally at the anterior end of the popliteal sulcus on the lateral femoral condyle. We found that the popliteus tendon has a constant broad-based femoral attachment on the most proximal half and anterior one-fifth of the popliteal sulcus. Stäubli et al.²³ also reported that the popliteus tendon slides into the groove of the popliteal sulcus when the knee is flexed. Our findings are in agreement with theirs. We found that, at an average of 112° of knee flexion, the popliteus tendon fell into the popliteal sulcus and remained in the sulcus with further knee flexion (Fig. 3); it anteriorly subluxated out of the sulcus when the knee was extended past this position. The popliteus tendon attachment on the femur was always anterior to the fibular collateral ligament femoral attachment. The average distance between the fibular collateral ligament and the popliteus tendon femoral attachments was 18.5 mm. This distance is useful to know when considering repair or reconstruction of these posterolateral knee structures.

Of the four posterolateral knee structures analyzed in the study, the popliteofibular ligament has perhaps been the cause of the most confusion and disagreement.^{16,22–25,31} In terms of its attachment to the popliteus, some studies have reported that the popliteofibular ligament attaches just proximal to the musculotendinous junction of the popliteus complex.^{24,28} However, we disagree with this finding. We found that the popliteofibular ligament attached to the musculotendinous junction of the popliteus and angled distolaterally to its attachment on the fibular styloid process. We concur with Stäubli et al.^{22,23} that the popliteofibular ligament has anterior and posterior divisions. In addition, we found, as they did, that the posterior division attached to the apex and downslope of the pos-

teromedial fibular styloid process and that the anterior division attached to the downslope of the anteromedial aspect of the fibular styloid process and had fibers extending to the lateral tibia near the proximal anterior tibiofibular ligament. We also found that the posterior division was consistently larger than the anterior division.

There have been many reports on procedures performed to stabilize the posterolateral knee.^{9,14,18,19,27,28} Although these reconstruction techniques attempt to reproduce the function provided by the posterolateral knee structures, they do not provide an anatomic reconstruction of the posterolateral knee structures. To our knowledge, there have been no reported studies on an anatomic reconstruction technique for the fibular collateral ligament, popliteus tendon, and popliteofibular ligament. With quantification of the attachment sites and with pertinent related bony anatomy locations to serve as reference points, we propose that further study be devoted to optimizing anatomic repairs/reconstructions of the posterolateral knee structures.

ACKNOWLEDGMENTS

This project was supported by the University of Minnesota Sports Medicine Research Fund of the Minnesota Medical Foundation. We express special thanks to Andrew Evensen for his assistance and perseverance in drawing the illustrations for this article.

REFERENCES

- Acker JH, Drez D: Analysis of isometric placement of grafts in anterior cruciate ligament reconstruction procedures. *Am J Knee Surg* 2: 65-70, 1989
- Arnoczky SP: Anatomy of the anterior cruciate ligament. *Clin Orthop* 172: 19-25, 1983
- Christel P, Djian P, Charon PH: Arthroscopic PCL reconstruction with two-bundle bone-tendon-bone autograft. *Arthroscopy* 15: S42, 1999
- Dye SF, Cannon WD Jr: Anatomy and biomechanics of the anterior cruciate ligament. *Clin Sports Med* 7: 715-725, 1988
- Fu FH, Schulte KR: Anterior cruciate ligament surgery 1996: State of the art? *Clin Orthop* 325: 19-24, 1996
- Gollehon DL, Torzilli PA, Warren RF: The role of the posterolateral and cruciate ligaments in the stability of the human knee. A biomechanical study. *J Bone Joint Surg* 69A: 233-242, 1987
- Good ES, Stowers SF, Noyes FR: Limits of movement in the human knee: Effect of sectioning the posterior cruciate ligament and posterolateral structures. *J Bone Joint Surg* 70A: 88-97, 1988
- Harner CD, Xerogeanes JW, Livesay GA, et al: The human posterior cruciate ligament complex: An interdisciplinary study. Ligament morphology and biomechanical evaluation. *Am J Sports Med* 23: 736-745, 1995
- Hughston JC, Jacobson KE: Chronic posterolateral rotatory instability of the knee. *J Bone Joint Surg* 67A: 351-359, 1985
- Kaplan EB: The fabellofibular and short lateral ligaments of the knee joint. *J Bone Joint Surg* 43A: 169-179, 1961
- LaPrade RF: Arthroscopic evaluation of the lateral compartment of knees with grade 3 posterolateral knee complex injuries. *Am J Sports Med* 25: 596-602, 1997
- LaPrade RF, Gilbert TJ, Bollom TS, et al: The magnetic resonance imaging appearance of individual structures of the posterolateral knee: A prospective study of normal knees and knees with surgically verified grade III injuries. *Am J Sports Med* 28: 191-199, 2000
- LaPrade RF, Terry GC: Injuries to the posterolateral aspect of the knee: Association of anatomic injury patterns with clinical instability. *Am J Sports Med* 25: 433-438, 1997
- Latimer HA, Tibone JE, El Attrache NS, et al: Reconstruction of the lateral collateral ligament of the knee with patellar tendon allograft. Report of a new technique in combined ligament injuries. *Am J Sports Med* 26: 656-662, 1998
- Lewis JL, Lew WD, Hill JA, et al: Knee joint motion and ligament forces before and after ACL reconstruction. *J Biomech Eng* 111: 97-106, 1989
- Maynard MJ, Deng X, Wickiewicz TL, et al: The popliteofibular ligament: Rediscovery of a key element in posterolateral stability. *Am J Sports Med* 24: 311-316, 1996
- Miller MD, Bergfeld JA, Fowler PJ, et al: The posterior cruciate ligament injured knee: Principles of evaluation and treatment. *Inst Course Lect* 48: 199-207, 1999
- Noyes FR, Barber-Westin SD: Surgical restoration to treat chronic deficiency of the posterolateral complex and cruciate ligaments of the knee joint. *Am J Sports Med* 24: 415-426, 1996
- Noyes FR, Barber-Westin SD: Surgical reconstruction of severe chronic posterolateral complex injuries of the knee using allograft tissues. *Am J Sports Med* 23: 2-12, 1995
- Seebacher JR, Inglis AE, Marshall JL, et al: The structure of the posterolateral aspect of the knee. *J Bone Joint Surg* 64A: 536-541, 1982
- Soames RW (ed): Skeletal system, in *Gray's Anatomy*. Thirty-eighth edition. New York, Churchill Livingstone, 1995, p 703
- Stäubli H-U, Birrer S: The popliteus tendon and its fascicles at the popliteal hiatus: Gross anatomy and functional arthroscopic evaluation with and without anterior cruciate ligament deficiency. *Arthroscopy* 6: 209-220, 1990
- Stäubli H-U, Rauschnig W: Popliteus tendon and lateral meniscus: Gross and multiplanar cryosectional anatomy of the knee. *Am J Knee Surg* 4: 110-121, 1991
- Sudasna S, Harnsiriwattanagit K: The ligamentous structures of the posterolateral aspect of the knee. *Bull Hosp Jt Dis Orthop Inst* 50: 35-40, 1990
- Sutton JB: On the nature of certain ligaments. *J Anat Physiol* 40: 34-50, 1884
- Terry GC, LaPrade RF: The posterolateral aspect of the knee: Anatomy and surgical approach. *Am J Sports Med* 24: 732-739, 1996
- Veltri DM, Deng XH, Torzilli PA, et al: The role of the popliteofibular ligament in stability of the human knee: A biomechanical study. *Am J Sports Med* 24: 19-27, 1996
- Veltri DM, Warren RF: Anatomy, biomechanics, and physical findings in posterolateral knee instability. *Clin Sports Med* 13: 599-614, 1994
- Veltri DM, Warren RF: Operative treatment of posterolateral instability of the knee. *Clin Sports Med* 13: 615-627, 1994
- Wascher DC, Grauer JD, Markoff KL: Biceps tendoneisis for posterolateral instability of the knee: An in vitro study. *Am J Sports Med* 21: 400-406, 1993
- Watanabe Y, Moriya H, Takahashi K, et al: Functional anatomy of the posterolateral structures of the knee. *Arthroscopy* 9: 57-62, 1993
- Wroble RR, Grood ES, Cummings JS, et al: The role of the lateral extraarticular restraints in the anterior cruciate ligament-deficient knee. *Am J Sports Med* 21: 257-263, 1993