The Effect of a Proximal Tibial Medial Opening Wedge Osteotomy on Posterolateral Knee Instability

A Biomechanical Study

Robert F. LaPrade,*† MD, PhD, Lars Engebretsen,‡ MD, PhD, Steinar Johansen,‡ MD, Fred A. Wentorf,† MS, and Chad Kurtenbach†

From the †Department of Orthopaedic Surgery, University of Minnesota, Minneapolis, Minnesota, and the ‡Department of Orthopaedic Surgery and Faculty of Medicine, Ullevaal University Hospital, University of Oslo, Oslo, Norway

Background: Increased stability of posterolateral corner knee injuries has been observed clinically after proximal tibial medial opening wedge osteotomies.

Hypothesis: Static varus and external rotatory stability will be significantly improved in a knee with a grade 3 posterolateral knee injury after a proximal tibial medial opening wedge osteotomy.

Study Design: Controlled laboratory study.

Methods: Biomechanical testing of 10 nonpaired, cadaveric knees was performed in the intact state after transection of the posterolateral corner (fibular collateral ligament, popliteus tendon, and popliteofibular ligament) and after a 10-mm proximal tibial medial opening wedge osteotomy. Loading conditions consisted of 12 N·m varus moments and 6 N·m external rotation torques. Six degrees of freedom motion analysis was used to assess motion changes, and a buckle transducer was used to measure the force on the superficial medial collateral ligament during applied loads.

Results: After transection of the posterolateral corner structures, a significant increase in varus rotation was found to applied varus moments with a mean increased opening of 5.9° to varus stress at 30° and 5.8° at 90° of knee flexion. After proximal tibial medial opening wedge osteotomy, varus rotation was increased by a mean of 1.6° at 30° and 1.7° at 90° of knee flexion compared with the intact state. There was a significant decrease in varus rotation to a varus moment after osteotomy compared with the posterolateral sectioned state at both 30° and 90°. External rotation of the knee increased by 4.7° at 30° and 4.8° at 90° after posterolateral structure sectioning compared with the intact state. After the osteotomy, there was a significant decrease in external rotation compared with the posterolateral sectioned state, and there was no significant difference in external rotation compared with the intact state. There was a significant increase in force on the superficial medial collateral ligament after the osteotomy compared with both the intact and posterolateral corner cut state for both an applied varus moment and external rotation torque at both 30° and 90°.

Conclusion: Our results demonstrate that a proximal tibial medial opening wedge osteotomy decreased varus and external rotation laxity for posterolateral corner–deficient knees. Concurrently, an increase in force was observed on the superficial medial collateral ligament compared with the native state.

Clinical Significance: The improved stability observed in some patients with grade 3 posterolateral knee injuries after a proximal tibial medial opening wedge osteotomy appears to at least in part be due to tightening of the superficial medial collateral ligament. The long-term consequences of the increased force on the superficial medial collateral ligament on the medial compartment, and whether it elongates with time, merit further investigation.

Keywords: posterolateral knee; proximal tibial medial opening wedge osteotomy; genu varus; biomechanics

Posterolateral knee injuries are often not diagnosed early and may present as chronic injuries that cause symptomatic functional limitations in patients. In this scenario, they are very difficult to treat because the results of surgical reconstructions have been inferior to those after acute repairs.[2,4,7,16,17] In addition, it has also been recommended that patients with varus alignment and symptomatic

*Address correspondence to Robert F. LaPrade, MD, PhD, Department of Orthopaedic Surgery, University of Minnesota, 2450 Riverside Avenue, R200, Minneapolis, MN 55454 (e-mail: lapra001@umn.edu).

No potential conflict of interest declared.

The American Journal of Sports Medicine, Vol. X, No. X
DOI: 10.1177/0363546507312380
© 2008 American Orthopaedic Society for Sports Medicine

chronic posterolateral knee injuries have their varus malalignment corrected first to reduce the risk of the soft tissue reconstruction grafts from stretching out.[1,7,15,17] It has been recommended in this situation that patients have a proximal tibial osteotomy to correct their malalignment first and then a soft tissue reconstruction once the osteotomy heals if they still experience functional instability.

It has been a clinical observation of our group and others that knees with combined grade 3 chronic posterolateral knee injuries and genu varus alignment often have an apparent reduction of increased abnormal laxity after a proximal tibial medial opening wedge osteotomy. In fact, some patients choose not to proceed with the second-stage soft tissue ligament reconstruction as they function quite well after regaining strength once the osteotomy heals. Therefore, the purpose of this study was to test this observation biomechanically to determine if a reduction in increased motion limits caused by a posterolateral knee injury occurs after a proximal tibial medial opening wedge osteotomy and, if so, the possible cause of this occurrence.

MATERIALS AND METHODS

Ten fresh-frozen cadaveric knees with an average age of 54 years (range, 39-67 years) were used in this study. All knees were examined to verify there was no evidence of osteoarthritis or instability before testing. All knees were kept at –20ºC and were thawed overnight before testing. On the morning of testing, the skin and subcutaneous tissues were removed, and the ends of the bones were shortened to 20 cm and potted in bone cement for testing. All knees were kept moist during testing with a saline spray.

The knees were subjected to loads in 3 different conditions. The biomechanical testing system involved has been previously reported on for the analysis of knee joint biomechanics,[3,10,11,14] which it provided for the simultaneous recording of loads by a pneumatic loading apparatus with its force transducers. It has been reported to have an accuracy of 0.67 mm for displacement and 0.73° for orientation.[14] First, the knees were tested in the intact state to loading at 30º and 90º of knee flexion. The loading conditions consisted of an 88-N anterior force, a 12-N·m varus moment, a 6-N·m internal rotation torque, a 6-N·m external rotation torque, and an 88-N posterior force. A 6 degrees of freedom video-based motion analysis system (Qualysis Inc, Glastonbury, Conn) with a reported accuracy to 0.1 mm[8] was used to measure joint motion for each testing condition. Buckle transducers were used to measure the forces applied to the superficial medial collateral ligament.[11-14] The buckles consisted of an outer rectangular frame with a removable crossbar seated on the frame. The ligament was placed between the crossbar and the frame. Tension on the ligament caused it to straighten out in the buckle transducer. The strain gauges, which were mounted in the frame, produced a voltage that was directly related to the tension created in the ligament, and the voltage was recorded during testing. Three testing cycles were performed for each joint-loading condition at each flexion angle and the results averaged. After testing was completed in the native intact state, it was repeated after cutting of the fibular collateral ligament, popliteus tendon, and popliteofibular ligament (to simulate a grade 3 posterolateral knee injury).[5,6,10,11,18,19]

After testing was completed in the normal and transected states, a 10-mm proximal tibial medial opening wedge osteotomy was performed (Puddu Plate; Arthrex Inc, Naples, Fla). A 10-cm incision was made over the anteromedial aspect of the proximal tibia, midway between the tibial tubercle and the posterior border of the medial tibia. Subperiosteal dissection was carried out anteriorly under the patellar tendon and deep intrapatellar bursa and posteriorly under the proximal attachment of the superficial medial collateral ligament and the popliteus muscle. Retraction was performed to protect the soft tissues, and a medial saw cut was performed following the sagittal plane slope of the medial tibial plateau 2 cm distal and parallel to the joint line. An oscillating saw and osteotomes were used to perform the osteotomy to within 1 cm of the lateral cortex. Motion analysis was used to verify that the osteotomy did not change the anterior or posterior sagittal tibial slope.

Once the osteotomy cut was completed, the opening wedge osteotomy was held open with a 10-mm plate, and 6.5-mm cancellous screws were placed proximally and 4.5-mm cortical screws were placed distally. In order not to alter the tibial slope, the plate was placed along the posteromedial tibia, deep to the superficial medial collateral ligament.[15] In addition, a 4.5-mm cortical screw was placed from distolateral to anteromedial across the osteotomy cut from just distal to the Gerdy tubercle into the medial tibial plateau to provide stability to the osteotomy construct during biomechanical testing (Figure 1). We found this extra stability screw was necessary in these cadaveric knees based on our findings that the lateral cortex eventually cracked in all 4 pilot knees toward the end of the testing cycle without this screw and resulted in gross instability at the osteotomy site.

Force measurements of specific structures were performed in 4 pilot knees by custom-made buckle transducers[11,13,14] for the superficial medial collateral ligament, oblique popliteal ligament, and the distal expansion of the semimembranosus tendon.[9] These structures were chosen for testing because they were the principal static structures that crossed the osteotomy site on the proximal tibia. However, we only found an increase in force on the superficial medial collateral ligament between the testing conditions in the pilot study, so the other 2 structures were not tested in the main study. In addition, after completion of the testing in 4 pilot knees, there was essentially no change in motion for the applied anterior and posterior forces as well as for an applied internal rotation torque. Therefore, these loading conditions were not tested in the main portion of this study.

Statistical analysis was performed for the measured motion differences for the 3 testing states for the different loading conditions using a 2-way analysis of variance (ANOVA; general linear model) with Bonferroni-adjusted 95% confidence intervals (CIs) calculated. Similarly, a 2-way ANOVA (general linear model) with 95% Bonferroni-adjusted CIs was calculated for the differences in medial collateral ligament loads between testing states and flexion angles. A P value of $< .05$ was considered to be significant.

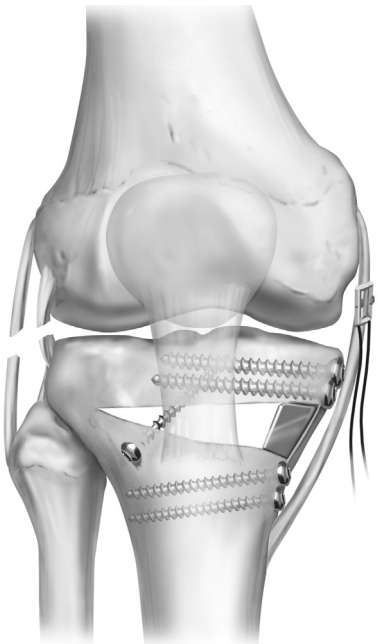

Figure 1. A right knee after the 10-mm proximal tibial opening wedge osteotomy was performed. Note that the posterolateral structures were sectioned, and there is a buckle transducer applied to the superficial medial collateral ligament.

RESULTS

The average posterior slope preoperatively was 8.9°, and there was no significant difference in the postoperative posterior tibial slope (9.3°). As mentioned previously, the lateral cortex fractured in all 4 pilot knees during varus load application after the osteotomy, so varus moments were applied last in the main portion of the study. All results are reported in averages with standard deviations (SDs) and Bonferroni-adjusted 95% CIs.

Varus Rotation to an Applied Varus Moment

After transection of the posterolateral corner structures, a significant increase in varus rotation was found to applied varus moments compared with the intact knee state with an increase of lateral joint opening of 5.9° (±1.5°; CI, 5.2°-6.5°) at 30° ($P < .001$) and 5.8° (±2.9°; CI, 5.0°-6.6°) at 90° ($P < .001$). After a proximal tibial medial opening wedge osteotomy was performed, varus rotation to an applied varus moment compared with the intact knee state was increased by 1.6° (±1.7°; CI, 1.0°-2.3°) at 30° ($P < .01$) and 1.7° (± 2.4°; CI, 0.9°-2.5°) at 90° ($P < .04$) (Figure 2). There was a significant decrease in varus rotation to a varus moment after the osteotomy compared with the posterolateral sectioned state at both 30º ($P < .001$) and 90º ($P < .001$).

External Rotation Motion to an Applied External Rotation Torque

External rotation of the knee to an applied external rotation torque at 30° increased by 4.7° (±2.4°; CI, 4.2°-5.2°) compared with the sectioned state with posterolateral sectioning ($P < .001$) and significantly decreased by 2.9° (±2.5°; CI, 2.4°-3.4°) compared with the sectioned state after the osteotomy ($P < .001$) (Figure 3). At 90° of knee flexion, external rotation of the knee to an applied external rotation torque significantly increased by 4.8° (±2.8°; CI, 4.3°-5.4°) compared with the intact knee ($P < .001$), and after performing an osteotomy, it decreased by 3.4° (±2.7°; CI, 2.8°-4.0°) compared with the sectioned state ($P < .001$). There was a significant decrease in external rotation to an applied external rotation torque after performing the osteotomy compared with the posterolateral sectioned state at both 30º ($P < .001$) and 90º ($P < .001$). There was no

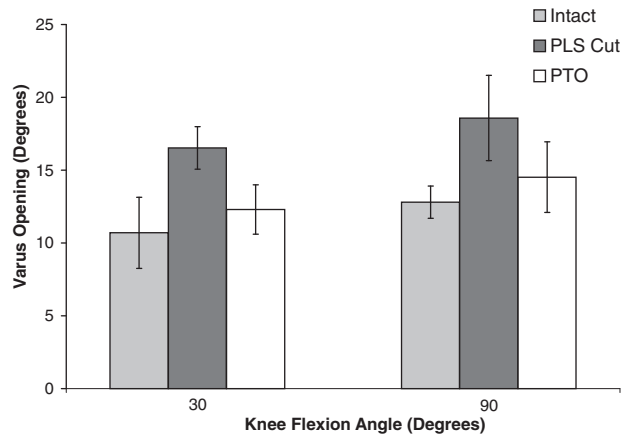

Figure 2. Mean varus rotation (with standard deviations) to an applied 12-N·m moment in intact knees, after sectioning of the main posterolateral structures (PLS) (fibular collateral ligament, popliteus tendon, and popliteofibular ligament) and after a 10-mm proximal tibial opening wedge osteotomy (PTO).

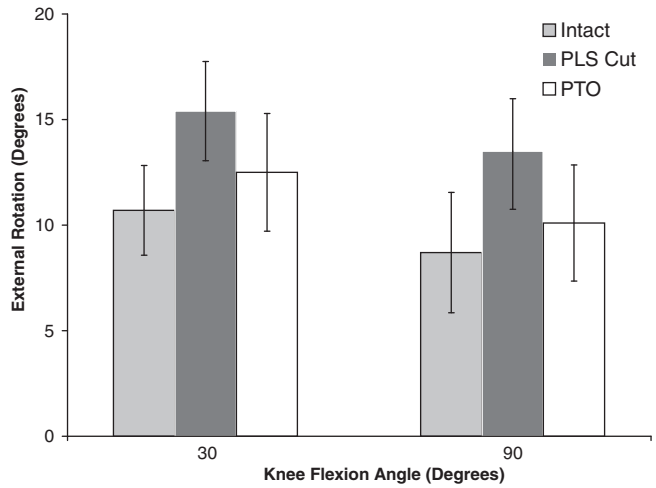

Figure 3. Mean external rotation (with standard deviations) changes to an applied 6-N·m external rotation torque in intact knees, after sectioning of the main posterolateral structures (PLS) (fibular collateral ligament, popliteus tendon, and popliteofibular ligament) and after a 10-mm proximal tibial opening wedge osteotomy (PTO).

significant difference in external rotation between the intact state and after performing the osteotomy at either knee flexion angle.

Force Measured Across the Superficial Medial Collateral Ligament to Applied Loads

At both 30° and 90° of knee flexion, the force measured across the superficial medial collateral ligament was 0 N for a varus moment in the intact knee and also after transection of the posterolateral corner structures because there was no stress applied to the medial knee structures with applied varus moments under these loading conditions. After a 10-mm proximal tibial medial opening wedge osteotomy, the mean force on the superficial medial collateral ligament with application of a varus moment was 61 N (±3.7 N; CI, 58.4-63.6 N) at 30º and 69 N (±5.8 N; CI, 64.9-73.1 N) at 90º. The increase in force on the superficial medial collateral ligament was significantly higher for a varus moment applied at 30º ($P < .001$) and 90º ($P < .001$) after the osteotomy compared to both the intact and posterolateral corner cut states.

The force on the superficial medial collateral ligament in the intact state for an external rotation torque was 105.9 N (±10.2 N; CI, 102.3-109.5 N) at 30º and 98 N (±12.2 N; CI, 90.5-105.5 N) at 90° (Figure 4). The force in the superficial medial collateral ligament following transection of the posterolateral corner structures was 116 N (±13.0 N; CI, 112.4-119.6 N) at 30° ($P < .01$) and 129.8 N (±17.1 N; CI, 121.5-136.5 N) at 90° ($P < .01$) for an external rotation torque. The force on the superficial medial collateral ligament after the osteotomy with application of an external rotation torque was 136.8 N at 30º (±14.5 N; CI, 133.2-140.4 N) ($P < .01$) and 174 N (±24.3 N; CI, 166.5-181.5 N) at 90º ($P < .001$) of knee flexion. The increase in force on the superficial medial collateral ligament was significantly higher for an applied external rotation torque at 30° and 90° after the osteotomy compared with both the intact and posterolateral sectioned states.

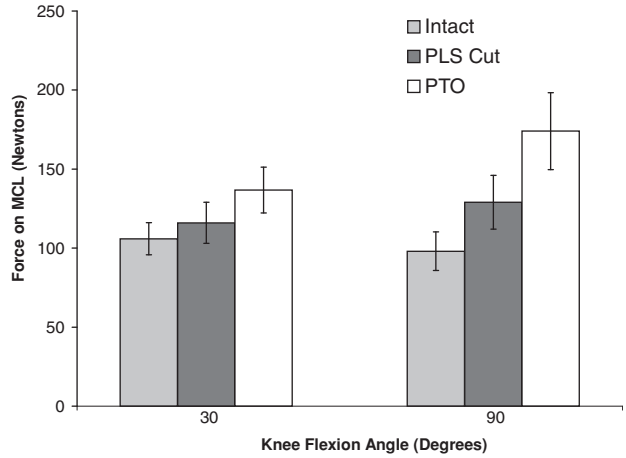

Figure 4. Mean forces (with standard deviations) seen on the superficial medial collateral ligament for an applied 6-N·m external rotation torque in the intact knee, after sectioning the main posterolateral knee structures (PLS) (fibular collateral ligament, popliteus tendon, and popliteofibular ligament) and after a 10-mm proximal tibial opening wedge osteotomy (PTO).

DISCUSSION

It has been noted by several sources that it is necessary to correct concurrent varus malalignment before soft tissue reconstructions of chronic posterolateral knee injuries.[1,7,15,17] Failure to correct varus malalignment has been noted to result in a high rate of failure of soft tissue posterolateral corner reconstructions due to the grafts stretching out.[15,17] It also has been observed that some patients have sufficient correction of their functional and objective instability after a proximal tibial medial opening wedge osteotomy to correct their varus malalignment that they do not need a second-stage soft tissue posterolateral reconstruction. While it may be debated if this may be due to either the change of their weightbearing mechanical axis at footstrike or tightening of some structures concurrent with the osteotomy, we have clinically noted that patients do have some detectable decreases in varus and posterolateral rotation abnormalities after a proximal tibial medial opening wedge osteotomy. This study confirms that a proximal tibial medial opening wedge osteotomy can tighten up the soft tissues around the knee, which secondarily results in a decrease in varus translation and external rotation instability.

We initially theorized that the majority of the stability provided to the knee after the proximal tibial medial opening wedge osteotomy would be provided primarily by a tightening of the posterior knee structures that crossed both the knee joint and the osteotomy site. However, the 1 structure that we found provided the majority of tightening with our biomechanical test setup was the superficial medial collateral ligament. In effect, there was no measurable force noted on the transverse fibers of the oblique popliteal ligament or the distal semimembranosus expansion over the popliteus muscle[9] with a proximal tibial opening wedge osteotomy. We theorize that the increased stability of the knee demonstrated after a proximal tibial opening wedge osteotomy may be more due to a secondary effect of tightening those structures with complex attachments to the superficial medial collateral ligament (the posterior oblique ligament and the deep medial collateral ligament) than to a direct tightening of the superficial medial collateral ligament itself. These structures have been noted to provide stability to the knee in external rotation and, through their attachment to the posterior capsule, may provide some of the stability to the knee in varus laxity also. The long-term implications of whether the tightening of the superficial medial collateral ligament—and its potential secondary tightening effect on the posterior oblique ligament and the deep medial collateral ligament—stretches out over time or if it possibly causes increased stress on the articular cartilage of the medial compartment of the knee are unknown.

One limitation of our study was that we did not know the alignment of the cadaveric knees before creating the osteotomy. However, the correction of varus alignment in

the treatment of posterolateral knee injuries is usually performed for correction of physiologic varus alignment, to prevent stretching out of the reconstruction grafts, rather than for the treatment of medial compartment arthritis. Thus, the shortened knees (30 cm total length) that were placed into our knee-testing machine could theoretically represent a similar relative alignment for a much longer extremity with more proximal or distal varus angulation.[10,11,14] In this regard, we believe that while the amount of force seen on the superficial medial collateral ligament to the applied loads may overestimate its normal load over time because of viscoelastic elongation of its tightened fibers, the end result of an increase in relative load seen on this structure, and the resultant increase in knee stability seen for varus and external rotations, appears to explain the clinical findings of the increase in knee stability seen in some patients after this type of osteotomy. In addition, we only tested 1 osteotomy plate size, and it is possible that different amounts of medial compartment opening may have resulted in different amounts of residual posterolateral laxity after an opening wedge osteotomy. And finally, it is possible that other structures that cross the knee may have influenced the decrease in knee instability after the proximal tibial opening wedge osteotomy.

Our results demonstrate that a proximal tibial medial opening wedge osteotomy decreased varus and external rotation in posterolateral corner–deficient knees in a laboratory model. Concurrently, an increase in force was observed on the superficial medial collateral ligament for an applied varus moment and external rotation torque compared with the native state. The increased force observed on the superficial medial collateral ligament helps to explain the increased stability observed in patients with chronic posterolateral corner knee injuries and genu varus alignment after undergoing a proximal tibial medial opening wedge osteotomy.

ACKNOWLEDGMENT

This study was supported by the University of Minnesota Sports Medicine Research Fund of the Minnesota Medical Foundation. No authors have received anything of benefit for the results of this project.

REFERENCES

1. Badhe NP, Forster IW. High tibial osteotomy in knee instability: the rationale of treatment and early results. *Knee Surg Sports Traumatol Arthrosc.* 2000;10:38-43.
2. Baker CL, Norwood LA, Hughston JC. Acute posterolateral rotatory instability of the knee. *J Bone Joint Surg Am.* 1983;65:614-618.
3. Coobs BR, LaPrade RF, Griffith CJ, Nelson BJ. Biomechanical analysis of an isolated fibular (lateral) collateral ligament reconstruction using an autogenous semitendinosus graft. *Am J Sports Med.* 2007;35(9):1521-1527.
4. DeLee JC, Riley MB, Rockwood CA. Acute posterolateral rotatory instability of the knee. *Am J Sports Med.* 1983;11:199-207.
5. Gollehon DL, Torzilli PA, Warren RF. The role of the posterolateral and cruciate ligaments in the stability of the human knee. A biomechanical study. *J Bone Joint Surg Am.* 1987;69:233-242.
6. Grood ES, Stowers SF, Noyes FR. Limits of movement in the human knee. Effect of sectioning the posterior cruciate ligament and posterolateral structures. *J Bone Joint Surg Am.* 1988;70:88-97.
7. LaPrade RF, Hamilton CD, Engebretsen L. Treatment of acute and chronic combined anterior cruciate ligament and posterolateral knee ligament injuries. *Sports Med Arthrosc Rev.* 1997;5:91-99.
8. LaPrade RF, Ly TV, Wentorf FA, Engebretsen L. The posterolateral attachments of the knee: a qualitative and quantitative morphology of the fibular collateral ligament, popliteus tendon, popliteofibular ligament, and lateral gastrocnemius tendon. *Am J Sports Med.* 2003;31(6):854-860.
9. LaPrade RF, Morgan PM, Wentorf FA, Johansen S, Engebretsen L. The anatomy of the posterior aspect of the knee: an anatomic study. *J Bone Joint Surg Am.* 2007;89(4):758-764.
10. LaPrade RF, Muench CW, Wentorf FA, Lewis JL. The effect of injury to the posterolateral structures of the knee on force in a posterior cruciate ligament graft. A biomechanical study. *Am J Sports Med.* 2002; 30:233-238.
11. LaPrade RF, Resig S, Wentorf FA, Lewis JL. The effects of grade III posterolateral knee complex injuries on anterior cruciate ligament graft force. A biomechanical analysis. *Am J Sports Med.* 1999;27(4): 469-475.
12. LaPrade RF, Tso A, Wentorf FA. Force measurements on the fibular collateral ligament, popliteofibular ligament, and popliteus tendon to applied loads. *Am J Sports Med.* 2004;32(7):1695-1701.
13. Lewis JL, Lew WD, Schmidt J. A note on application and evaluation of the buckle transducer for knee ligament force measurement. *J Biomech Eng.* 1982;104:125-128.
14. Lewis JL, Lew WD, Schmidt J. Description and error evaluation of an in vitro knee joint testing system. *J Biomech Eng.* 1988;110:238-248.
15. Noyes FR, Barber-Westin SD. Anterior cruciate ligament revision reconstruction results using a quadriceps tendon patellar bone autograft. *Am J Sports Med.* 2006;34:553-564.
16. Noyes FR, Barber-Westin SD. Surgical restoration to treat chronic deficiency of the posterolateral complex and cruciate ligaments of the knee joint. *Am J Sports Med.* 1996;24:415-426.
17. Noyes FR, Barber-Westin SD, Hewitt TE. High tibial osteotomy and ligament reconstruction for varus angulated anterior cruciate ligament deficient–knees. *Am J Sports Med.* 2000;28:282-296.
18. Terry GC, LaPrade RF. The posterolateral aspect of the knee. Anatomy and surgical approach. *Am J Sports Med.* 1996;24:732-739.
19. Veltri DM, Deng X-H, Torzilli PA, Maynard MJ, Warren RF. The role of the popliteofibular ligament in stability of the human knee: a biomechanical study. *Am J Sports Med.* 1996;24:19-27.